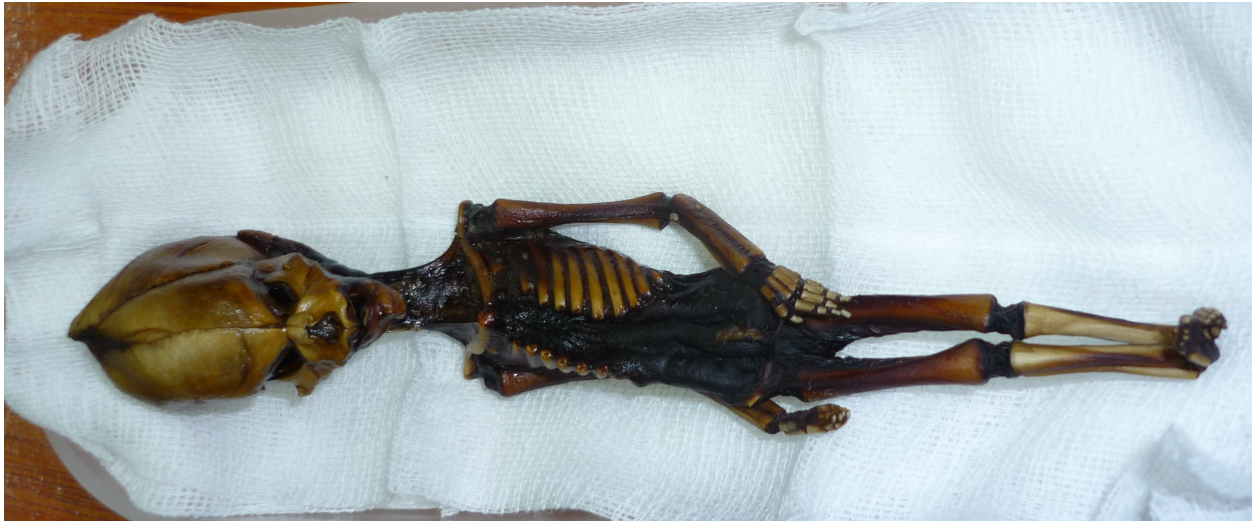

Stanford University Research: Atacama Humanoid Still A Mystery
Steven M. Greer MD
22 April 2013

After six months of research by leading scientists at Stanford University, the Atacama Humanoid remains a profound mystery.



The humanoid was first discovered in 2003 in the remote Atacama desert region of Chile, but I did not learn of the existence of the specimen until 2009, when invited to examine the mummy-like remains of the humanoid in Barcelona Spain. In the summer of 2012, Ramón Navia-Osorio Villar, President of INSTITUTO DE INVESTIGACIONES Y ESTUDIOS EXOBIOLÓGICOS graciously permitted our team to do further tests on the humanoid.

We traveled to Barcelona Spain in late September 2012 to obtain detailed X Rays, CAT scans and take genetic samples for testing at Stanford University.

Dr. Garry Nolan , the Rachford and Carlota A. Harris Professor in the Department of Microbiology and Immunology, Stanford University School of Medicine, headed up the team examining the human-like specimen . He suggested the protocol for taking the DNA samples and, in consultation with Dr. Ralph Lachman, also of Stanford University, suggested precisely which X Rays and CT scan images would be needed for proper evaluation of the skeletal anomalies.

Dr. Lachman, who is a visiting scholar and visiting professor at Stanford University and author of “ Radiology of Syndromes, Metabolic Disorders and Skeletal Dysplasias” and is one of the leading experts in the world on skeletal dysplasia and abnormalities, examined the X Rays, CAT scans and photographs of the humanoid.

We obtained excellent DNA material by surgically dissecting the distal ends of two right anterior ribs on the humanoid. These clearly contained bone marrow material, as was seen on the dissecting microscope that was brought in for the procedure. The bone marrow and other material from the skull were obtained under sterile, surgical procedures and placed directly into sterile containers provided by Dr. Nolan.

Using forensic documentation procedures, this evidence was then hand-delivered by me to Dr. Nolan in Washington DC in October, 2012.

Dr. Nolan proceeded to set up a very detailed protocol needed for examining "ancient" or old DNA. This is a highly specialized area of research and the leading scientists in the world with expertise in this area consulted with Dr. Nolan in this endeavor.

The Atacama Humanoid is a 13 centimeter, or 6 inch, body that is very desiccated but completely intact. The CAT scan clearly shows internal chest organs (lungs and what appears to be the remains of a heart structure).(See CAT scan [here](#)) There is absolutely no doubt that the specimen is an actual organism and that it is not a hoax of any kind. This fact has been confirmed by Dr. Nolan and Dr. Lachman at Stanford.

The specimen has only 10 ribs, a finding not yet found in humans, and a very unusual cranium. It is noted that the cranial vault is, proportionally, much larger than is found in normal humans. The bones are quite well developed and are not those of a fetus (see below). There are multiple skeletal anomalies seen throughout the specimen. Importantly a mature, not fetal, tooth is seen in the mandible (jaw bone) A fracture of the right humerus (upper arm) is seen as is a concave fracture of the right posterior-lateral skull, which was most likely the cause of death.

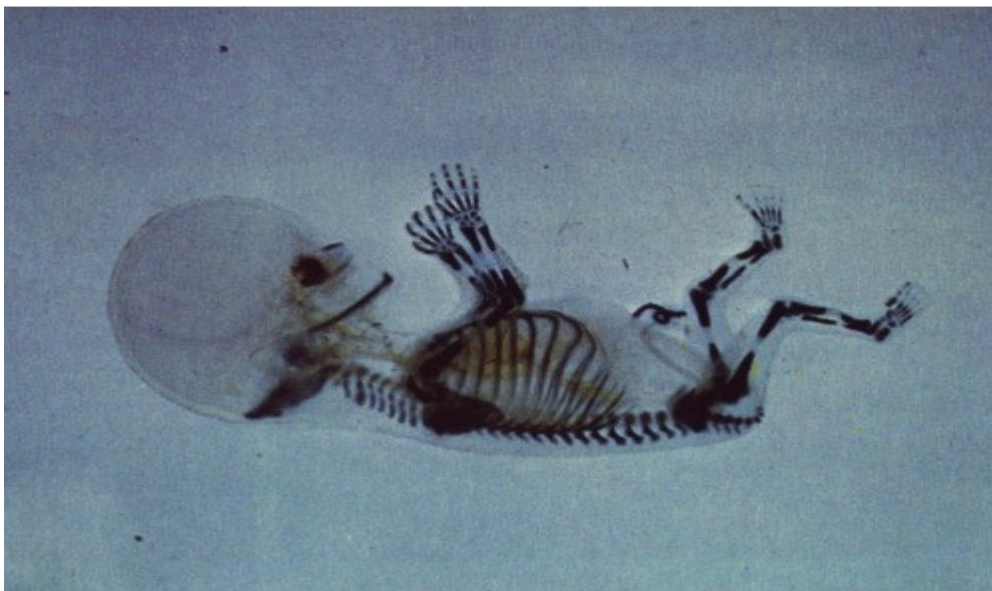

Illustration 1: Human Fetus, 2 Months

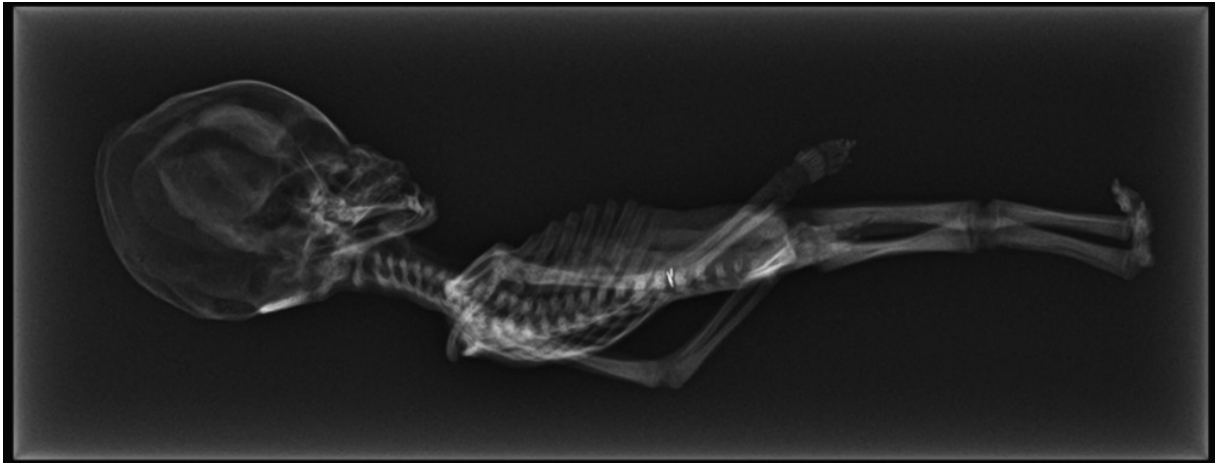


Illustration 2: Atacama Humanoid

Importantly, Dr. Lachman has concluded that the humanoid is NOT any known deformity, genetic defect, skeletal dysplasia or any other known human abnormality. However, the most startling conclusion to date is that Dr. Lachman concluded the humanoid lived to be 6- 8 years of age. (See Dr. Lachman's full report [here...](#)). This was assessed by examining the epiphyseal plates in the knees and comparing these to normal humans of various ages.

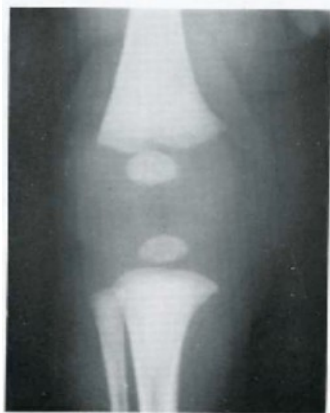


Illustration 3: Human Knee, 1 Month

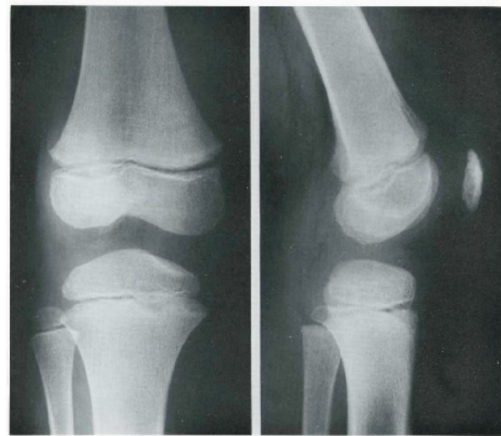


Illustration 4: Human Knee, 6

He noted that there is no known form of human dwarfism that has this presentation and set of findings. No human is known to be able to live for 6-8 years and remain only 6 inches in length.

It should be noted also that Dr. Manchon, of the Manchon Radiology Center in Barcelona, also examined the X Rays and concluded that the specimen was most certainly not a fetus and had lived for a year or more and probably several years.

Previously, there had been false reports published elsewhere that the humanoid was a fetus.

This is clearly not the case as can be concluded from the research of Dr. Lachman and the examination by Dr. Manchon. A comparison of fetus X Rays shows a remarkable difference between human fetus skeletal development and the X Rays of the Atacama humanoid.

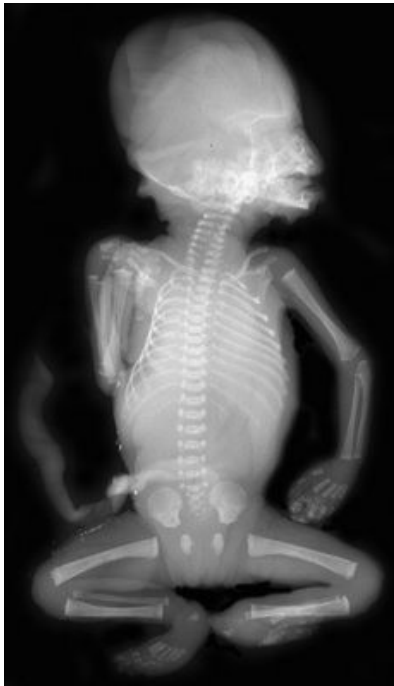

Illustration 5: Human Fetus

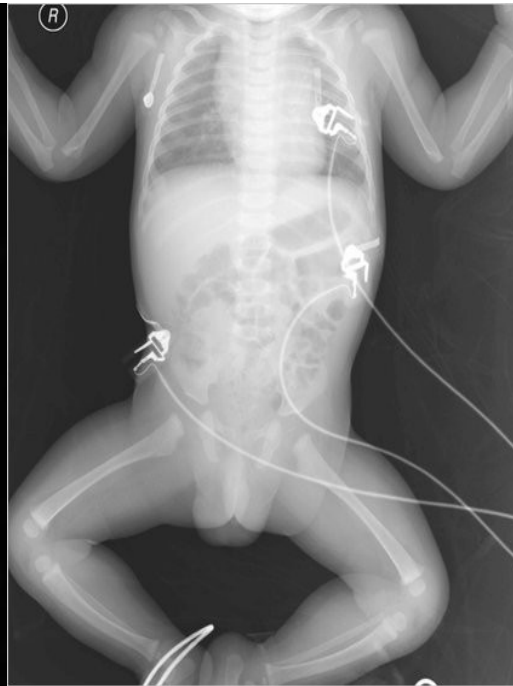


Illustration 6: Human Newborn

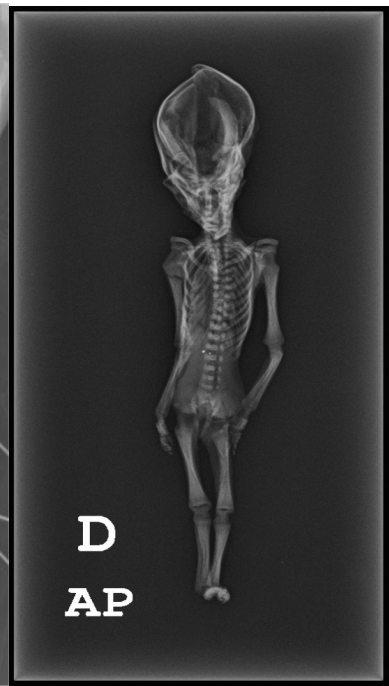

Illustration 7: Atacama Humanoid

Painstaking and expert DNA extraction was done by Dr. Nolan at Stanford University. A very high quality and quantity of DNA was successfully extracted and analyzed.

Only Preliminary analysis of the DNA has been done to date, and Dr. Nolan notes that it may be a year or more before full manual analysis and confirmation can occur.

Dr. Nolan notes: "The DNA was of high quality, showing little to no serious degradation."

Dr. Nolan also notes that: "Sequence analysis definitively rules out the specimen as an example of a New World primate."

Importantly, Dr. Nolan has found that: "Preliminary results demonstrate no statistically relevant alterations of genes encoding proteins commonly associated with known genes for primordial dwarfism or other forms of dwarfism. Therefore, if there is a genetic basis

for the symptoms observed in the specimen the casual mutation(s) are not apparent at this level of resolution and at this stage of the analysis. “

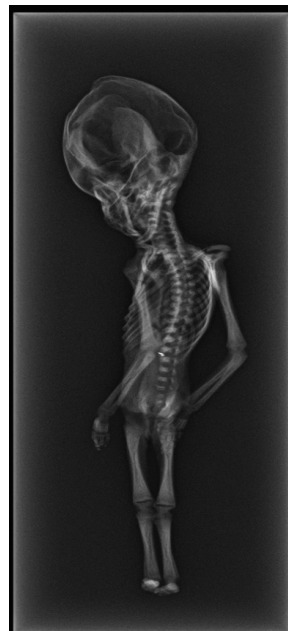
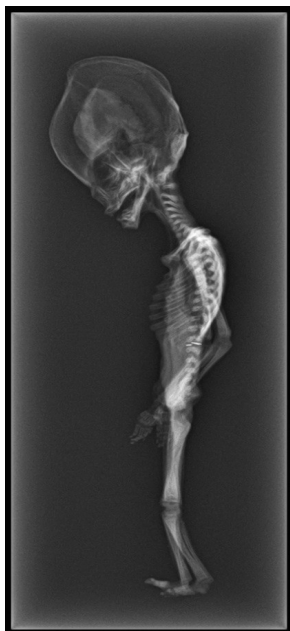
It should be noted that Neanderthals are 99.5% genetically identical to humans, and chimps and apes are 96-97% identical.

As of this date, the genotype does not seem to match the phenotype (meaning physically expressed form of the genetics).

The answer to this mystery will lead in further analysis of the DNA and confirmation of the findings through the peer review process.

Dr. Nolan's report (see full report [here](#)) concludes by stating further research is needed:

“This preliminary report demonstrates how currently available biomedical technologies can be readily applied to the analysis of archeologically and anthropologically relevant human specimens with genetic disorders of unknown origin. This report is not a formal conclusion on the nature of the mutations or the underlying cause of the disorder in this human specimen. Currently the data represents (conservatively) a 15 fold whole genome reading and as such is insufficient for definitive conclusions. Future plans include continued study of this specimen to establish up to a 50 fold WHS read that could point to targeted sequencing of hypothetical causal mutations. Comparison of the observed sequence variations against recently developed ethnically focused genome databases is planned. Full analysis of the DNA, and attempts to link genetics to morphology, will eventually follow in an appropriately peer-reviewed article in an accredited scientific journal. The results will be independently verified before publication.”



Clinically, given that this humanoid lived many decades to centuries ago (exact date remains unknown but it is not a recently living specimen) it is hard to understand how a 6 inch baby or child could have lived to be 6-8 years of age in such a remote and undeveloped part of the world. Even in today's best Neonatal Intensive Care Unit (NICU) we would hardly be able to keep such a specimen alive. As an emergency physician, I have delivered premature infants, as well as a significantly deformed one with anencephaly, and am struck by how small and fragile this humanoid is. Medically speaking, IF this is merely a deformed human, it does not seem feasible that he would have lived to be 6-8 years of age. Speaking as a clinician, I, as well as other doctors with whom I have spoken, doubt he would have lived 6 hours. consistent with a human fetus of this size.

Given how long ago he lived and how primitive that area would have been- totally lacking in modern medical technologies and facilities- how would this child have lived? And with whom? Certainly there are many more questions than answers at this juncture.

The mystery is further compounded by the reports from Ramon Navia-Osorio Villar and his associates who traveled to the region and obtained information from local native peoples of sightings of UFOs and very small living creatures fitting the general description of this humanoid. There are also reports that other intact humanoids may be stored in various remote sites and locations. These reports have not been confirmed, however.

It is necessary to do much more thorough research into this case. The DNA work is really in it's early stages, and we need to take a scientific expedition to the Atacama desert to see if there are more examples of this humanoid- and to see if indeed there is on-going UFO/ ET activity in that region as reported.



HYPOTHESIS AND THOUGHTS

If the genetics continue to show a human connection to this humanoid, what does this mean? We cannot say the Atacama Humanoid is an ET. Nor is he any known – or clinically conceivable - human that could have lived. So who is he? He remains a mystery, and perhaps- just perhaps- a doorway to discovering much about who we are.

Recently, some scientists (see [here](#)) working on DNA and computer analysis found that DNA has been around for over 10 billion years- but earth has been here for less than half that time. Perhaps life is indeed universal, and Contact spreads life from world to world...

I have discussed with other scientists the possibility of epigenetic augmentation of the human genome. Is the Atacama Humanoid a so-called hybrid? Are we all some type of hybrid? Could this have occurred via contact with other extraterrestrial civilizations over millions of years? A source who refuses to be identified stated to me several years ago that he had seen a National Security Agency document that concluded that there had been 64 epigenetic augmentations of the human genome in the past that has resulted in modern humans. Could this be possible?

A Jet Propulsion Laboratory (JPL) scientist once told me that the reason the objects found on and near Mars - like the obelisks that Astronaut Buzz Aldrin want us to go back to Mars to examine- would show an ancient connection between ETs and humans- and that this is why that information is being kept classified. When I asked why, he said "Because the foundations of every fundamentalist orthodox belief system on earth would be up-ended".

To pursue science is to pursue the truth of matters. What is needed from this point going forward is an open mind so that, together, we may discover the truth about many things yet hidden.